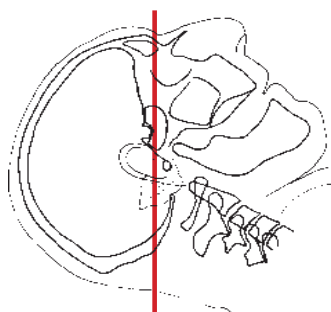
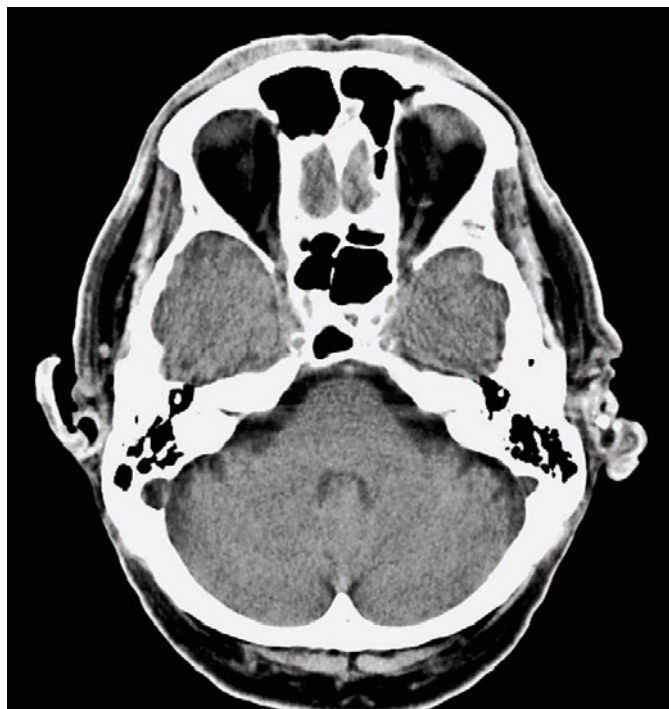




-  Frontal lobe
-  Temporal lobe
-  Cerebellum
-  Pons